

# Novel applications of a bioactive resin in perforations, root resorption and endodontic-periodontic lesions

Dr Marta Maciak, Poland

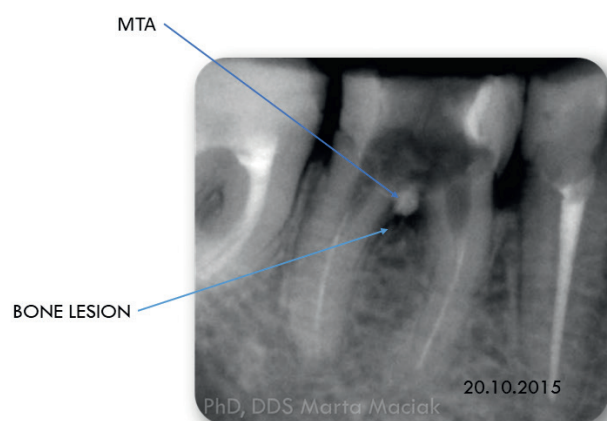


Fig. 1

## Introduction

During the last decade, a considerable amount of attention has been directed towards the development of so-called bioactive materials. To understand this phenomenon better and to avoid misinterpretation, a condensed review of the literature and an assessment of various definitions need to be considered.

There are already several commercially available dental materials that can be defined as bioactive. For instance, any fluoride-releasing material, calcium silicate- and calcium aluminate-based cements, and calcium-based or calcium-containing materials. Biomaterial scientists in the field of implantology have adopted the word "bioactive" to mean materials that are bound to each other through a biomineralised interface. There appears to be confusion within the dental profession, including among scientists, clinicians and industry persons, to what extent biomineralisation can be achieved with dental materials and which materials can be appropriately termed "bioactive" or "biomineralising".<sup>1</sup>

Bioactivity has been defined and can be interpreted in various ways. A broad definition that has several meanings is the following: a material that is able to have a biological effect or a material that is biologically active and forms a bond between the tissue and the material.<sup>2</sup> In the field of tissue engineering, the term "bioactivity" is related to the cellular effects induced by the release of biologically active substances and ions from the biomaterial, for example from bioactive glasses both in soft- and hard-tissue engineering applications.<sup>3, 4</sup> In addition, its activity

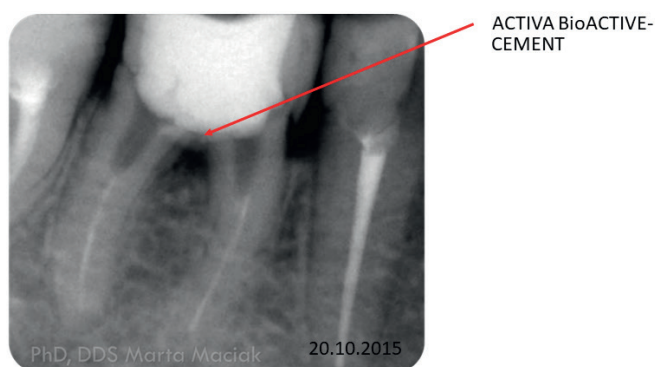


Fig. 2

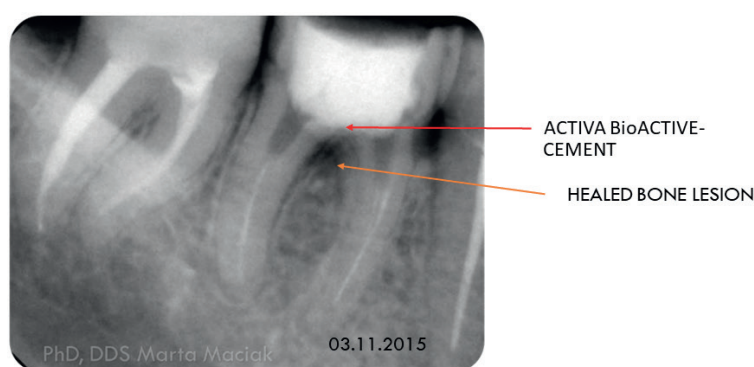


Fig. 3

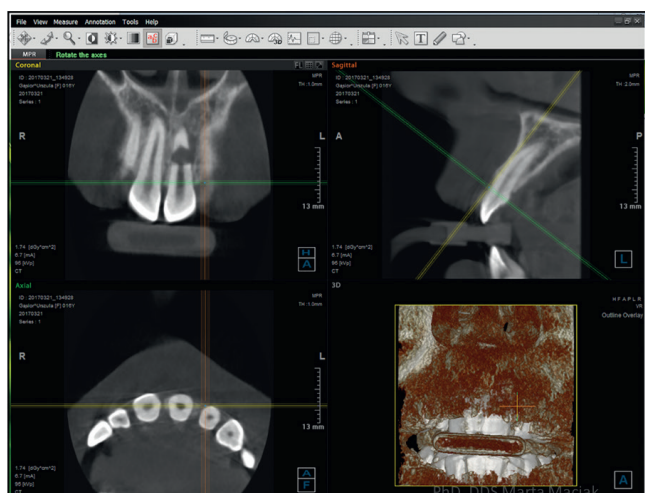


Fig. 4

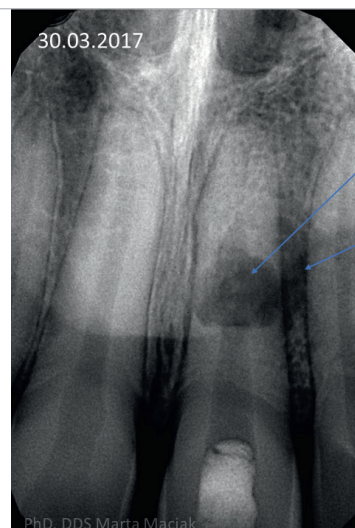


Fig. 5

PhD, DDS Marta Maciak

has been demonstrated in pulp capping experiments in non-human primates.<sup>5</sup>

Thus, in medicine, bioactivity covers all interaction of materials with living cells and tissue, including the effects of pharmaceuticals. In biomaterial science, with bioceramics and bioactive glasses, bioactivity of a material usually denotes that the material is capable of forming hydroxyapatite minerals on its surface *in vitro* and *in vivo*.<sup>6</sup>

The following theoretical question should be asked: can a material that releases ions for biomineralisation be considered bioactive or is the substrate on which the biomineralisation occurs bioactive? Thus, bioactivity of dental materials relates to their potential to induce specific and intentional mineral attachment to the dentine substrate.<sup>7</sup>

Another definition has been presented in an article by Löf et al.: "Bioactivity of a ceramic material is a surface

property that provides a bond between the material and living tissues without fibrous encapsulation."<sup>8</sup> In yet another definition, bioactivity is described as follows: "A bioactive material is one that forms a surface layer of an apatite-like material in the presence of an inorganic phosphate solution."<sup>9</sup>

ACTIVA BioACTIVE-RESTORATIVE and ACTIVA BioACTIVE-BASE/LINER (Pulpdent) have been shown to exhibit bioactive properties based on this last definition. ACTIVA BioACTIVE products are the first dental resins with a bioactive ionic resin matrix. They have a shock-absorbing rubberised resin component and reactive ion-omer glass fillers that mimic the physical and chemical properties of natural teeth. These bioactive materials actively participate in the cycles of ion exchange that regulate the natural chemistry of the teeth and saliva and contribute to the maintenance of tooth structure and oral health. ACTIVA has the strength, aesthetics and physical properties of resin composites and is more bioactive than glass ionomer cements.<sup>10</sup> ACTIVA seals teeth against mi-

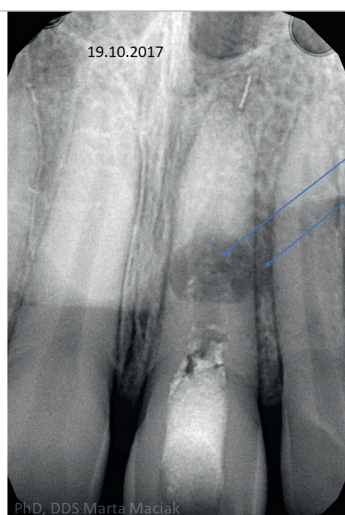


Fig. 6

PhD, DDS Marta Maciak

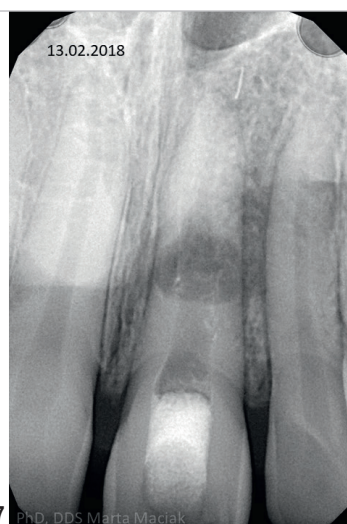
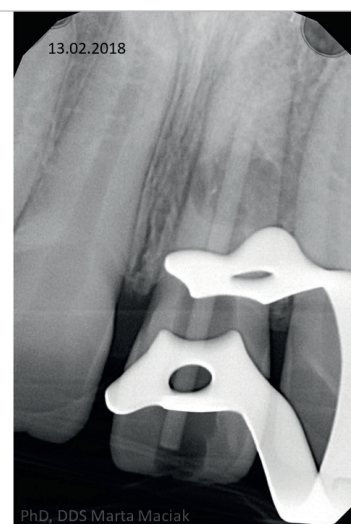


Fig. 7

PhD, DDS Marta Maciak



PhD, DDS Marta Maciak

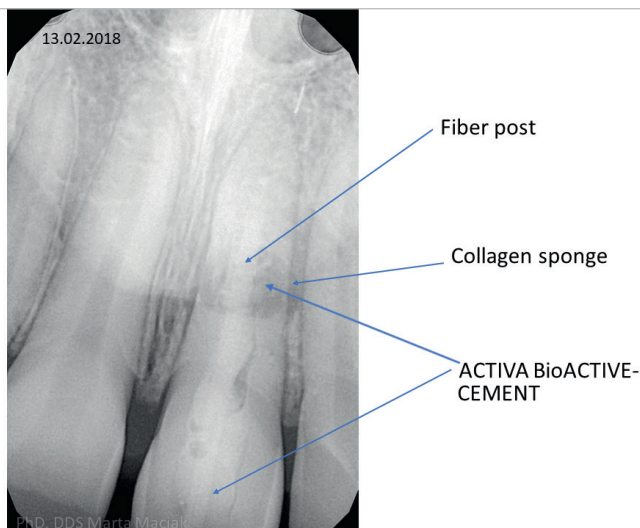


Fig. 8

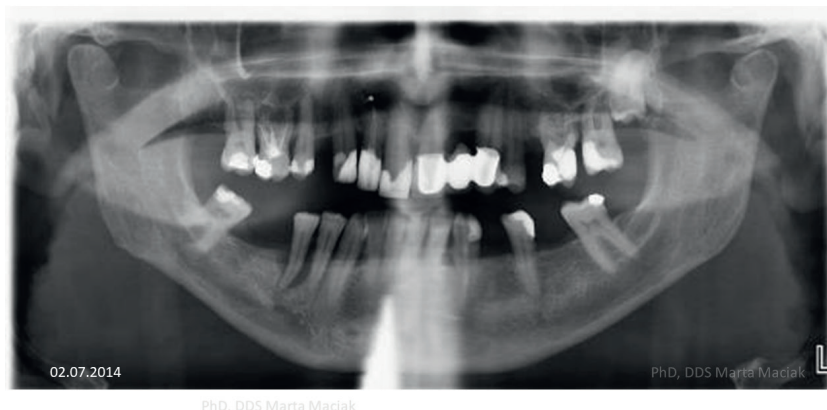

Fig. 9

creoleakage<sup>11, 12</sup> and its continuous release and recharge of significant amounts of calcium, phosphate and fluoride ions provide patients with long-term benefits.

In the US, the bioactivity claim for ACTIVA, being the first bioactive resin material, has been accepted. Based on its strength and durability due to a patented rubberised resin molecule that absorbs stress and resists fracture, the author has used ACTIVA BioACTIVE-RESTORATIVE and ACTIVA BioACTIVE-BASE/LINER in lieu of mineral trioxide aggregate (MTA) and Biodentine (Septodont) for selected endodontic and other procedures.

The cases presented here are off-label treatments using ACTIVA BioACTIVE-BASE/LINER in cases with a poor prognosis and in which extraction (and an implant) may have seemed a more obvious choice of therapy. These procedures are not listed in the company's indications for use and were carried out by the author after explaining the possible potential benefits, as well as the risks to the patient. All of the patients agreed to the treatment and signed an informed consent form for endodontic treatment.

#### Case 1

A 28-year-old female patient was referred and presented with pain of tooth #46. The referral letter stated that endodontic retreatment was needed and the perforation had been closed with MTA. The patient was in considerable pain when eating and when closing her mouth. Her medical history did not present any contraindications to dental treatment.

The clinical examination showed a temporary filling in tooth #46. A radiograph taken on 20 October 2015 showed extrusion of MTA into the furcation, as well as a bony defect (Fig. 1). Perforation of the floor of the pulp chamber was diagnosed.

Upon removal of the temporary filling, a large amount of purulent exudate filled the pulp chamber and was evacuated. After the MTA had been removed, the furcation was flushed with metronidazole (liquid; Polpharma) and 2% chlorhexidine (Cerkamed). The borders of the perforation were refreshed with a carbide bur, and then the pulp chamber was etched with 37% orthophosphoric acid for 10 seconds, followed by a thorough rinse. Through the perforation, a collagen sponge (ANTEMA, Molteni Dental) was applied to support the ACTIVA BioACTIVE-BASE/LINER and to protect the underlying bone defect. The sponge was not visible on the radiograph. The canal orifices were protected with cotton pellets and the entire pulp chamber was treated with a dentine bonding agent (DenTASTIC UNO, Pulpdent), which was light-cured, and then covered with ACTIVA BioACTIVE-BASE/LINER, covering the floor of the pulp chamber (Fig. 2).

The tooth was closed with GIZ glass ionomer (Ihde Dental) as a temporary filling. The patient was pain-free within two days. A follow-up radiograph taken on 3 November 2015 (14 days postoperatively) showed the beginning of the healing of the bone in the furcation area (Fig. 3).

#### Case 2

A 16-year-old patient was referred with root resorption of tooth #21. A CBCT scan and radiograph (Figs. 4 & 5) taken on 30 March 2017 clearly demonstrated the root resorption. Note the temporary filling in the pulp chamber. The patient's medical history was non-contributory. The diagnosis was mixed internal and external root resorption.

After removal of the temporary filling, inflamed granulation tissue was seen inside the canal. In spite of the fact that the apical portion of the canal was calcified, it was located. The canal was shaped and cleaned with the Self-Adjusting File (SAF) System (ReDent Nova) and

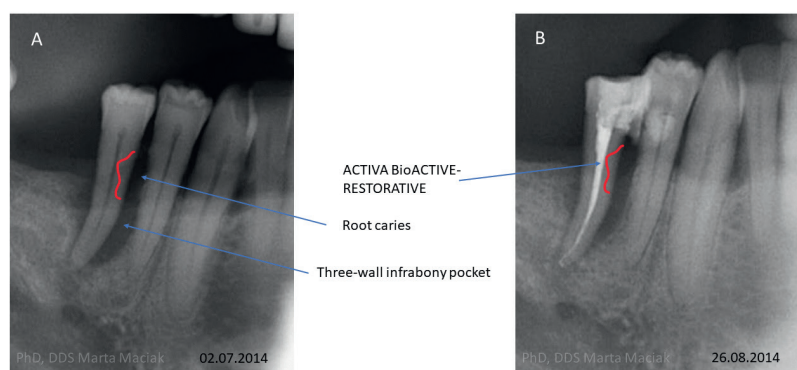


Fig. 10

XP-endo Finisher (FKG Dentaire), and flushed with 5.25 % sodium hypochlorite (NaClO), 17 % EDTA (Cerkamed) and metronidazole (Polpharma). As a first temporary canal filling, Dexadent (Chema-Elektromet) was applied for one week to treat the inflammatory tissue in the canal. During subsequent visits, the canal was rinsed with 40% citric acid (Cerkamed) and 2 % chlorhexidine (Cerkamed) using the SAF System and XP-endo Finisher. A temporary filling of Multi-Cal (Pulpdent) mixed with 2 % chlorhexidine (liquid) was inserted into the canal. Initially, the temporary dressing was replaced every two weeks to accomplish removal of granulation tissue and to stimulate bone regeneration. Over the course of about seven months, a reduction of the bone lesion was observed, as evidenced by radiographs (Fig. 6) and CBCT and under high magnification.

The final treatment after approximately 11 months (Fig. 7) consisted of cleaning the canal with the XP-endo Finisher and EDTA and 2% chlorhexidine irrigation. The resorption area was plugged with a collagen sponge (Antema) to provide support for ACTIVA BioACTIVE CEMENT and to prevent it from flowing beyond the root structure. A dentine bonding agent (All-Bond Universal, Bisco) was applied to the canal space, but not polymerised, just slightly air-dried, and the root was filled from the apex to the pulp chamber with ACTIVA BioACTIVE-BASE/LINER. A fibre post (Cytec blanco, Hahnenkratt) was immediately placed, following which the pulp chamber was filled with ACTIVA. After 20 seconds, the restoration was light-cured from three different directions for 20 seconds each.

The final result can be seen on a radiograph from 13 February 2018. Complete bone healing adjacent to the resorption area was observed (Fig. 8). While the radiograph shows the fibre post, the collagen sponge and ACTIVA BioACTIVE CEMENT do not possess sufficient radiopacity to be seen on a radiograph.

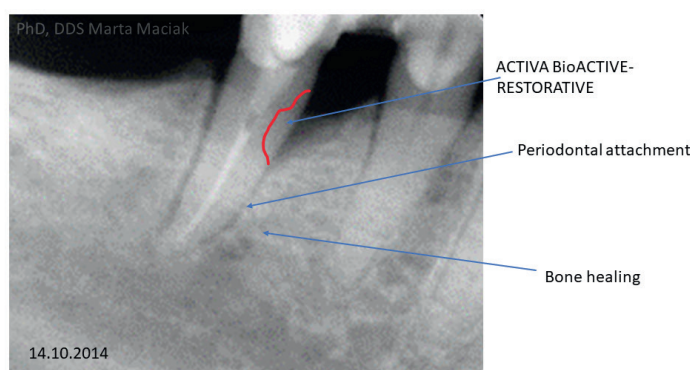


Fig. 11

### Case 3

A 63-year-old female patient presented for dental treatment. A panoramic radiograph (Fig. 9) revealed a heavily restored dentition with single crowns, a three-unit bridge and multiple missing teeth in both arches. She complained of pain in the mandibular right premolar area. Her medical history did not present any contra-indications to dental treatment.

When the patient was informed that tooth #45 would have to be extracted, she objected and asked if anything could be done to save it, even if only on a temporary basis, as she was reluctant to commit to wearing a removable partial denture. She thus consented to a treatment that offered no guarantee of success.

Clinical examination showed third-stage luxation and pus in the gingival pocket. A radiograph showed a three-wall infrabony pocket (Fig. 10A) reaching the apex of the root. The diagnosis was periapical periodontitis with purulent exudate and root caries on the mesial aspect. The treatment consisted of endodontic and periodontal treatment after a panoramic radiograph and realtime polymerase chain reaction (PET test, PET Plus, MIP Pharma) were performed.

Endodontic treatment was performed on 2 July 2014 with a HyFlex file of size 25.04 (COLTENE) and the SAF System. The pus was evacuated from the root canal and the canal was flushed with 5.25% NaClO and metronidazole, and Dexadent ointment was applied and left for one week. To avoid extra expenses, no bone grafting material was used; only a deep curettage was performed.

An occlusal cavity was prepared and filled with ACTIVA BioACTIVE-RESTORATIVE, and the tooth was splinted to the adjacent premolar with fibreglass and ACTIVA (Fig. 10B). The purpose of the splint was to lend

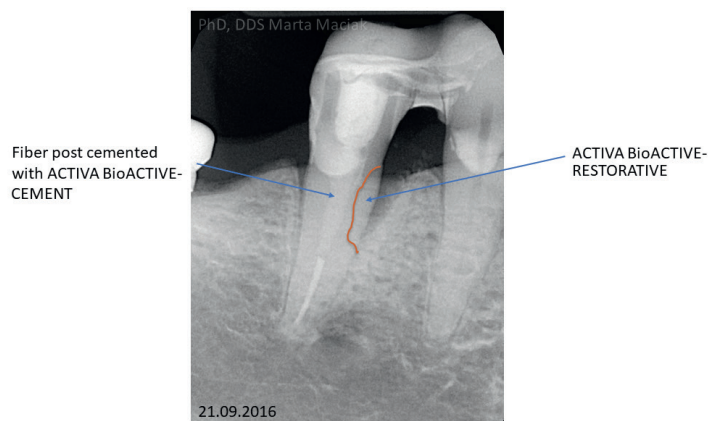


Fig. 12

support to the tooth, which presented with a Class III mobility, thus promoting healing. After a few days, the patient reported being free of pain, and no exudate in the canal was observed.

On 10 July 2014, the canal dressing was changed to Multi-Cal mixed with 2% chlorhexidine and left for a period of two weeks. Two weeks later, the Multi-Cal was removed with the SAF System using 40% citric acid and distilled water. Then the canal was rinsed with 2% chlorhexidine and dried with suction. GuttaFlow (COLTENE) was used as a sealer, and a master cone was softened in chloroform and placed in the canal. Vertical hot condensation was carried out in the apical part. The remainder of the root canal was filled with a continuous wave of gutta-percha. The period until the next appointment determined whether the treatment would be successful or not. Healing of the infrabony lesion continued during this period (Fig. 11).

Three months later, the gutta-percha was partially removed from the canal, which was etched and rinsed, followed by application of the dentine bonding agent (All-Bond Universal). The canal was filled with ACTIVA CEMENT and a fibre post was placed, and after 20 seconds, it was light-cured (Fig. 12). After three years, a radiograph showed complete bone healing and periodontal attachment (Fig. 13).

## Conclusion

Based on the available published research and after early favourable results had established the effectiveness of ACTIVA BioACTIVE materials, and based on the pH, release of calcium and phosphate ions and apatite formation in the presence of saliva, the decision was made to expand the number of suitable cases. Although a favourable outcome could not be guaranteed, clinical cases followed over a period of three and more years

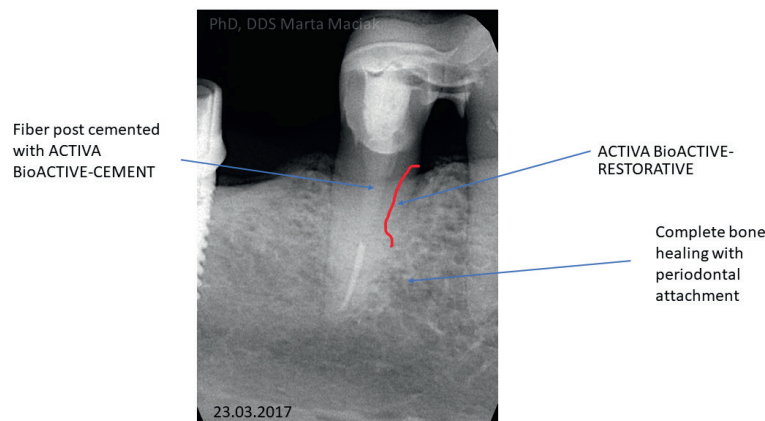


Fig. 13

presented with positive results and provided evidence that the bioactive properties of ACTIVA BioACTIVE materials through their ability to stimulate apatite formation and osteoblasts provided a viable treatment option. The evidence has been presented here with radiographs and CBCT scans showing new bone formation. Although histopathological evidence has not been provided, a periodontal evaluation demonstrated periodontal attachment in the cases presented here.

*Editorial note: A list of references is available from the publisher.*

## contact



**Dr Marta Maciak, PhD**, graduated with a DDS from the Medical University of Białystok in Poland in 1999. In 2007, she graduated with a specialty in conservative dentistry and endodontics from the university's Department of Restorative Dentistry. From 2004 to 2009, she was an

assistant in the same department. In 2009, she received a PhD in medical sciences in dermatology. She is a member of the Polish Dental Association and Polish Endodontic Association. She has authored many publications, and since 2005, she has lectured in Poland and numerous other countries, in addition to presenting practical training in the fields of endodontics and aesthetic dentistry. Her main interests are aesthetic dentistry, endodontics and prosthetics. She can be contacted at [martamaciak2012@gmail.com](mailto:martamaciak2012@gmail.com).